



PATIENT

Zoey Brandt

SPECIES

Canine

BREED

Schnauzer Mix

SEX

Female Spayed

AGE

11 years

WEIGHT

15lbs

INTERPRETED BY

Maggie Machen Lamy,
DVM, DACVIM
(Cardiology)

IMAGING PERFORMED BY

Rachel Runnells, RVT

HOSPITAL NAME

SVS Imaging KC

REFERRING VET

Dr. Meineka

INVOICE

22724

DATE

2/21/22

PRESENTING CLINICAL SIGNS

History: Presented July 2021 for evaluation for coughing, previous veterinarian had diagnosed her with tracheal collapse. At that time had been having multiple episodes of honking cough and panting. Rads revealed dorsal tracheal deviation and intra-thoracic tracheal narrowing. Right atrium appeared enlarged on rads. Began treatment with hydrocodone PRN and Cerenia daily, decreasing to every other day. Over the last several months she had been doing very well with 6 mg Cerenia once daily every other day. Owner reports that when the Cerenia is wearing off she will have coughing episodes so severe that she passes out.

ECHOCARDIOGRAM FINDINGS

2D, m-mode, color flow and doppler imaging is available. Normal mitral valve leaflets with no prolapse into the left atrial lumen. Trivial mitral regurgitation with no left atrial dilation. Normal LV diameter with adequate myocardial function. The tricuspid valve appears normal with trivial tricuspid regurgitation. Normal velocity. Normal right atrial and ventricular diameter and morphology indicating no overt evidence of pulmonary arterial hypertension. The pulmonic and aortic valves are normal in morphology and mobility. Normal pulmonic and aortic outflow velocities with laminar flow. No obvious aortic and trace pulmonic insufficiency. No pericardial or pleural effusion noted. No obvious cardiac masses.

CARDIAC CHART

CANINE CARDIAC PARAMETERS	MR VMAX (m/s)	TR VMAX (m/s)	LA/AO (Boon method)	LA/AO (Heart Base; Swe)	FS (%)	EF (%)	EPSS (cm)
NORMAL PARAMETER	4.5-5.5	<2.7	1.3	<1.6	28-40	40-100	<0.6
PATIENT	5.1	2.0	1.4	1.0	46	80	0.2
CANINE CARDIAC PARAMETERS	HR (BPM)	AV VMAX (m/s)	PV MAX (m/s)	BODY WEIGHT (kg)	LA 2D short axis Base view (cm)	LVIDd Avg; 2D and m-mode short axis (cm)	LVIDs Avg; 2D and m-mode short axis (cm)
NORMAL PARAMETER	50-100	0.7-1.7	0.7-1.6	BELOW	BELOW	BELOW	BELOW
PATIENT	95	1.6	0.9	6.8	1.3	2.4	1.3
*Normal chamber parameters expressed as a mean value (SD)				3	1.27 (5.3)	2.46 (2.46)	1.36 (5.5)
BODY WEIGHT DEPENDENT PARAMETERS				5	1.40 (4.5)	2.74 (5.2)	1.60 (4.7)
<i>*Note: All measurements based upon multi-modal images and methods. An average value is reported.</i>				10	1.50 (3.8)	3.27 (3.5)	2.06 (3.1)
				15	1.83 (2.0)	3.71 (2.4)	2.43 (2.1)
				20	2.02 (1.9)	4.14 (2.2)	2.80 (2.0)
				25	2.18 (2.4)	4.48 (2.9)	3.10 (2.5)
				30	2.33 (3.3)	4.83 (3.9)	3.39 (3.4)
				35	2.48 (4.3)	5.17 (5.0)	3.69 (4.5)
				40	2.62 (5.2)	5.48 (6.1)	3.96 (5.4)
				50	2.88 (7.1)	6.07 (8.3)	4.46 (7.4)

INTERPRETATION OF THE FINDINGS & FURTHER RECOMMENDATIONS

Overtly normal cardiac dimensions and function, with no obvious dysfunction or dilation of the left heart. Trivial leaks are noted in the mitral and tricuspid valves, which are suspected to be physiologic in origin. No other significant valvular leaks are visualized, and no evidence of pulmonary hypertension. The TR velocity is normal, further supporting this assumption.

IMAGING PERFORMED BY

svsmobileimaging.com 309-737-3070

**PATIENT**

Zoey Brandt

SPECIES

Canine

BREED

Schnauzer Mix

SEX

Female Spayed

AGE

11 years

WEIGHT

15lbs

INTERPRETED BYMaggie Machen Lamy,
DVM, DACVIM
(Cardiology)**IMAGING PERFORMED BY**

Rachel Runnels, RVT

HOSPITAL NAME

SVS Imaging KC

REFERRING VET

Dr. Meineka

INVOICE

22724

DATE

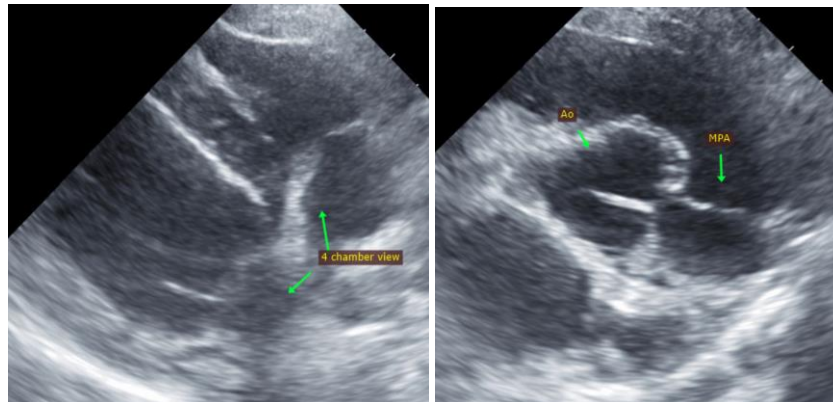
2/21/22

No cardiac medications are indicated at this time as the cough appears non-cardiac in origin. No obvious PAH is seen; however, this may certainly develop in the future. The best approach is adequate cough control to decrease inflammation. Continued work up for infectious/inflammatory respiratory causes of the cough is recommended. Options include Baytril or similar antibiotic, anti-inflammatory prednisone, more aggressive hydrocodone, etc. If refractory, may consider TTW/BAL for further information.

Cough associated syncope is likely due to hypoxia. More adequate cough suppression should help decrease this symptom.

Monitor for development of a heart murmur, cough, labored breathing, exercise intolerance or collapse episodes.

Chronic respiratory issues can lead to pulmonary hypertension if poorly controlled and a recheck echocardiogram is recommended should any exertional syncope/dyspnea occur, or a murmur be noted in the future.

IMAGES

The information and recommendations provided are based on the images presented by the referring veterinarian. No evaluation can be communicated regarding pathology that was not visible in the image/video clips provided.

Thank you for this referral. If the clinical or image interpretation does not parallel your findings or if I can be of any further assistance, please contact me.

Maggie Machen Lamy, DVM
 Diplomate of the American College of Veterinary Internal Medicine (Cardiology)
 info@sonopath.com